

# Clinical Advances in Head & Neck Surgery

## Chapter 3

# Surgical Therapy of Headaches: Minimally Invasive Approaches

*Edoardo Raposio\**; Nicolò Bertozzi; Chiara Bordin; Francesco Simonacci

*Parma University Hospital, Plastic Surgery Chair, University of Parma, Italy*

*Correspondence to: Edoardo Raposio, Cutaneous, Mininvasive, Regenerative and Plastic Surgery Unit, Parma University Hospital, Plastic Surgery Chair, University of Parma, Italy.*

*Email: edoardo.raposio@unipr.it*

---

## Abstract

During the last few years, multiple studies have demonstrated the efficacy of migraine and tension-type headache trigger site deactivation surgery, hence expanding the therapeutic potentiality of plastic surgery. These procedures are performed based on headache onset location: 4 trigger points that may cause the compression of the trigeminal branches have been described. In the present chapter we describe indications, contraindications, procedures and results of this therapy, focusing on our approach that relies on one 1-cm incision and it is performed under local anesthesia.

**Keywords:** Migraine; Tension-type headache; Surgical therapy; Endoscopic surgery; Minimally invasive surgery

## 1. Introduction

Migraine Headaches (MH) affect over 324.1 million people worldwide [1]. Despite its prevalence and debilitating nature, MH is still widely undiagnosed and undertreated. The direct and indirect cost due to MH treatment accounts for \$13 to \$17 billion each year only in the United States (US) [2]. Every year 112-million workdays are missed because of MH, with a \$14 billion annual loss of productivity in the US [3]. MH has an even greater burden on patients' everyday life, their families and the society.

Traditionally, MH has been managed with a combination of non-pharmacologic (behavioral) treatment and abortive or preventive drugs. Despite advancements in pharmaceutical therapies (the annual cost of medications alone is \$1.5 billion), almost 30% of MH patients are refractory to standard treatment and still suffering from persistent MH.

Furthermore, numerous side effects are reported in literature as consequence of chronic MH drugs use, such as fatigue, dizziness, cardiovascular arrhythmias, cerebral, myocardial, and peripheral ischemia, hypertension and hepatotoxicity.

Over the years various hypotheses have been proposed to reveal MH etiology. Researchers have attributed MH origin to central neurovascular phenomena, cortical neuronal hyperexcitability, cortical spreading depression, and abnormal modulation of brain nociceptive system; lastly, central and peripheral activation with sensitization of the trigeminal system was casted as main MH cause [4]. What is clear is that MH pathophysiology is still a matter of debate.

Plastic surgeons were not looking for a surgical treatment for MH, however this idea made its way in 1999 following the report made by patients that described elimination or improvement in their MH after corrugator supercilii muscle resection for forehead rejuvenation surgery [4]. In 2000, Guyuron et al. first reported in a retrospective study this association between corrugator supercilii muscle resection and disappearance or significant improvement in MH attacks. In the same years, independent studies demonstrated the efficacy of botulin toxin injection for the treatment of MH [4].

These evidences supported the hypothesis that MH was determined by peripheral activation of the trigeminal nerve, due to overstimulation of its branches (trigger points), followed by peripheral and central sensitization [5]. The trigger site is defined as the point where the MH starts and corresponds to the anatomical area of potential irritation of the trigeminal nerve [5]. Consequence of the mechanical stimulation and irritation of the trigeminal nerve is the release of calcitonin gene-related peptide, substance P, and neurokinin, which are found in cell bodies of trigeminal nerves [4,5]. These neuropeptides may cause the activation of the trigemino vascular system and the neurogenic inflammation that are followed by meningeal irritation, altered micro vascular blood flow, central and peripheral trigeminal sensitization recognized as hyperalgesia and cutaneous allodynia.

The hypothesis that compression of craniofacial nerves could play a key role in triggering migraines has been strengthened by multiple anatomical studies demonstrating that musculature, vessels, bony foramen, and facial bands can entrap or compress nerve branches at proposed migraine trigger sites [5,6].

Over the last 15 years, Guyuron conducted several studies providing foundation for this hypothesis and reported a reduction of the frequency, duration, and intensity of MH by at least half in 80 to 90% of patients [4,6-8]. In the same years, other independent groups reported similar findings using Guyuron's protocols, demonstrating the effectiveness of the procedure and the reproducibility of the results [5]. However, the most striking evidence for the effectiveness of peripheral nerve decompression surgery for MH therapy derived from

a double-blind, sham-controlled study conducted by Guyuron in 2009 [7]. In this trial, 49 patients underwent decompressive surgery while 26 underwent sham surgery. At least 50% reduction in MH was reported from 57.7% patients of the sham surgery group and 83.7% in the actual surgery group (p 0.05). Moreover, 57.1% of actual surgical group reported complete elimination of MH symptoms, compared with only 3.8% patients in the sham surgery group (p 0.001). At 1 year, all migraine headache measurements were significantly improved in the actual surgical group and were not dependent on the trigger site.

Researchers have established that deactivation surgery could be performed at four main trigger sites and two less common ones [9].

1. Frontal Trigger (Site I): patients with frontal symptoms; glabellar muscles or vessels may irritate the supratrochlear and supraorbital nerves.
2. Temporal Trigger (Site II): patients with temporal headaches; temporalis muscle or vessels may cause inflammation of the zygomatic-temporal branch of the trigeminal nerve.
3. Rhinogenic Trigger (Site III): patients complain of paranasal and retrobulbar headaches; deviated septum, contact between the turbinate's and the septum, concha bullosa, septa bullosa and other intranasal abnormality may irritate the trigeminal end branches. This site will not be covered in the present chapter.
4. Greater Occipital Trigger (Site IV): patients refer occipital symptoms; occipitalis, trapezius and semispinalis capitis muscles, facial bands or occipital artery can irritate the greater occipital nerve.
5. Auriculotemporal Trigger (Site V): patients complain temporal headaches; in the preauricular and temple region the superficial temporal artery and facial bands may be the cause of auriculotemporal nerve irritation.
6. Lesser Occipital Trigger (Site VI): patients refer occipital symptoms; trapezius and sternocleidomastoid muscles, fascial bands and occipital artery branches may compress the lesser occipital nerve.

Essential step is detecting the precise site of pain onset [10]. Although patients may report diffuse headache, once they are asked to locate where the pain begins, they can precisely identify it by pointing with one fingertip and that's where the surgical treatment must be focused on in order to release the nerve branch involved. Surgeons can confirm the correct localization of the trigger point by simple compression on the tender point, which usually evoke pain. Nerve blocks and the use of a portable Doppler device could also confirm the trigger points and may help surgeons until they develop sufficient comfort and expertise, while pre-operative botulinum toxin injections have proven to be useless. Lack or incomplete response should be

carefully interpreted as does not automatically exclude the suspected trigger point. Thus, the analysis of patients' symptoms and the physical examination can reliably guide the surgical planning.

Therefore, the mechanism of surgical deactivation of MH trigger sites is similar to carpal tunnel surgery or other nerve decompression techniques. There are strong evidences that surgical treatment for MH can successfully eliminate or reduce the MH frequency, intensity and duration in a lasting manner, reducing the economic burden of MH suffers, improving patients' performances and participation in daily-life activities [2,9]. However there is still a percentage of patients that are refractory to surgery [6]. Possible explanation is the incomplete detection of all of the trigger sites or that the irritation sites were not correctly dealt by current surgical approaches [5]. Rigorous patient screening and selection, proper identification of MH trigger points are mandatory for successful surgical outcome; yet a thorough understanding of the anatomy is essential to ensure complete nerve release and prevent postoperative complications.

## **2. Surgical Anatomy**

### **2.1. Frontal region**

The frontal region constitutes the upper third of the face. It is an unpaired and median anatomic region, which extends from the hair margin of the scalp to the eyebrows overlying the supra orbital rim. It consists of multiple tissue layers: there are the skin, which here is the thickest of the face, a subcutaneous layer of fibro-adipose tissue and a myofascial layer. The myofascial portion lays on the periosteum of the frontalis bone [11].

The muscles of the frontal region can be divided in two groups regarding their function. For the elevators' group there is the frontal belly of the occipitofrontalis, whose insertions to the deep layer of the skin are distributed from the aponeurotic galea to the brow level, where the superior arc of the periorbital septum provides an indirect bony origin [11]. The depressor group features the glabellar muscle group, including the procerus, the corrugator supercilii, the depressor supercilii and the orbicularis oculi muscles. These muscles extend through the galeal fat pad before giving off their dermal insertions and are often blended with fibers of the frontalis muscle.

The procerus is a small, triangular muscle that originates from the fascia of the nasal bone and inserts into the glabellar and forehead skin. Superior to the procerus there is the corrugator supercilii muscle, a small pyramidal muscle, which extends obliquely over the supra orbital rim. It has two heads, transverse and oblique. The first one is found from the nasal process of the frontal bone to the dermis at the middle third of the brow while the second one is smaller and parallel to the fibers of the depressor supercilii. The depressor supercilii muscle

arises from the medial orbital rim, near the lacrimal sac and inserts on the medial aspect of the bony orbit, inferior to the corrugator supercilii. The orbicularis oculi is a flat elliptical muscle which surrounds the orbit and spreads in the adjacent regions of the eyelids, anterior temporal region, infraorbital cheek and superciliary region. It divides into an orbital, preseptal and pretarsal portion. The orbital portion arches around the orbit stemming from the nasal component of the frontal bone, the frontal process of the maxilla and from the medial canthal tendon. The preseptal or palpebral portion overlies the orbital septum with its fibers originating from the superficial surface of the medial canthal tendon and from the bone immediately above and below it, and then converging at the lateral palpebral raphe. The pretarsal or lacrimal portion lies over the tarsus and its fibers adhere to it following an elliptical path and laterally interlace with the lateral raphe. A number of ligamentous attachments are found in the frontal region stemming from the temporal ligamentous adhesion. It arises from the periosteum of the frontal bone and it forms a triangular structure 20 mm high with a base of 15 mm situated 10 mm above the arcus marginalis of the rim and parallel to it. Three ligaments radiate from it: the superior and inferior temporal septum, belonging to the temple region, and the supraorbital adhesion. They are responsible for the compartmentation of the forehead and the brow together with the periorbital septum which divides the orbital region into the periorbital and orbital compartments.

The supraorbital ligamentous adhesion is located between the temporal ligament and the origin of the corrugator muscle. Its inferior border lies 6 mm above the deep attachment of the periorbital septum, while the upper border is not well-defined and extends cranially a variable of 20 to 40 mm above the orbital rim.

The periorbital septum connects the inferomedial origin of the orbicularis oculi with that of the corrugator muscle, occupying three-quarters of the orbital rim. In the periorbital portion it continues as the fibrous periosteum, while the orbital region goes on to form the orbital septum. These structures avoid contributing to ocular complication as a consequence of the surgical decompression of the nerves, since they are effective in isolating the oedema in the forehead region, and are dissected within the surgical decompression of the supraorbital and the supratrochlear nerves [4-6,12].

The supraorbital nerve is a sensory nerve originating from the frontal branch of the ophthalmic division of the trigeminal nerve. In the majority of the cases it passes through a supraorbital notch, which can be occasionally completed by a fibrous band. It can also exit through a foramen situated 1,5 mm above the supraorbital rim. Multiple exit points can be found in some patients: respectively in 16% and 18% on the right and left side. At this point the nerve divides into a superficial and a deep branch although it can split before exiting the supraorbital rim in a minority of the cases [5]. Here the nerve displays an intimate relationship with the corrugator supercilii muscle.

The traditional nerve topography was recently reviewed and four types of branching patterns were described [5]. In 40% of the cases the deep division only leaves strands deep to the frontalis muscle (type I), in 34% both divisions send branches (type II) and in 4% it is the superficial division that arborizes (type III). In the rest of the cases (type IV) the branches emerge mostly from the superficial division cranially to the corrugator muscle.

The reason why some patients do not respond to the surgical decompression of only the supraorbital nerve and need a more medial muscular resection is that the supratrochlear nerve may be involved.

The supratrochlear nerve is the smallest terminal branch of the frontal nerve, which itself originates from the ophthalmic division of the trigeminal nerve. It emerges between the trochlea and the supraorbital foramen. The exit point of the supraorbital nerve can be either a foramen or a notch, with findings of a notch present on both sides being more frequent. However it should be noted that it is also possible to discover a notch on one side and a foramina on the other or rarely a bilateral foramina; the first potential compression point of the nerve can be located here. The floor of the notch is in fact a fibrous band which surrounds the nerve. Compression symptoms appear frequently in two instances: firstly when the nerve passes through the band itself, secondly when the band appears to be very thick [5].

The emergence patterns were classified in two main types. In 69% of the cases the nerve emerges from the medial portion of the supraorbital rim independently either as a single branch (type Ia) or as two separated branches (type Ib). In the remaining cases the supraorbital and the supratrochlear nerve appear to come out at the same point (type II). Moreover, type II was further divided into two subtypes: IIa and IIb, depending on whether the nerve emerges as a single trunk or as two branches.

The nerve then ascends through the forehead and passes through the fat pad behind the orbicularis oculi and it pierces the corrugator muscle. The point where it enters the muscles has a mean distance of 16.4 mm from the midsagittal line and of 2.3 mm from the supraorbital rim. Furthermore, both its entrance and its exit from the muscle are possible compression points [4]. There is a significant individual variability in the relationship between the muscle and the nerve. Normally the nerve divides into two branches within the thin retro-orbicularis oculi fatty tissue and these branches follow four possible paths. Most commonly (84%), both branches pierce the muscle (type I). In type II one branch enters the muscle and one remains deep to the muscular plane. Type III is where both branches run deep and don't pierce the muscle. Type IV is when they leave immediately fine branches that cannot be identified [5].

Another source of compression can be the interaction of nerves with the vascular structures.

The main vessels that may be involved are the supratrochlear and the supraorbital artery.

The supratrochlear artery passes through the frontal notch and runs medial to the nerve and can be found around the medial canthal vertical line. In a third of the cases the artery crosses underneath the nerve deep to the corrugator from medial to lateral. It then pierces the corrugator supercillii and reaches the subcutaneous layer from 15 to 25 mm above the supraorbital rim.

The supraorbital artery can be found in a vertical line corresponding to the medial limbus of the cornea, sharing its course with the supraorbital nerve.

Another vascular structure that could be involved is the frontal branch of the superficial temporal artery, which enters the frontal region at different transverse levels at the lateral orbital rim vertical line. It runs superficial to the frontalis muscle and becomes progressively more superficial moving medially [11].

## 2.2. Temporal region

The temporal region corresponds to the lateral part of the skull; it is a paired anatomical region lying above the zygomatic arch in front of the external ear. It is limited superiorly by the superior and inferior temporal lines, and inferiorly and laterally by the zygomatic arch.

The tissues are arranged in two main layers: the superficial and the deep fascia. The superficial temporal fascia consists of a continuous layer including the galea aponeurotica, the SMAS (superficial muscular-aponeurotic system) in the zygomatic and cheek region and the platysma. It is composed by thin skin, loose areolar subcutaneous tissue and the flat muscles. Deep to this plane it can be found a potential space characterized by loose tissue.

Connecting the superficial to the deep fascia and the periosteum there is a system of ligamentous attachments. These structures are the temporal ligamentous adhesion and the ligamentous structures that origin from it, particularly the superior temporal septum and the inferior temporal septum. They retain the superficial tissues, limiting the possibility of dissection in this area.

The superior temporal septum extends from the junction between the superficial temporal fascia and the galea toward the periosteum along the superior temporal line of the cranium. It ends 30 mm from the orbital rim providing a firm adhesion, while posteriorly it forms a septum.

The inferior temporal septum extends from the lateral corner of the temporal ligament to the external acoustic meatus, following an oblique path.

The temporal region can be divided in the upper temporal compartment, enclosed between these two septa, and the lower temporal compartment, located under the inferior temporal septum, limited inferiorly by the zygomatic arch and anteriorly by the frontal process

of the zygoma.

The upper compartment is not crossed by any relevant structures and tissues here are easy to dissect. On the contrary, the lower one presents different fibrous attachments of criss-crossed fibers. The surgical separation of these planes is harder to achieve because of these adhesions and also for the presence of multiple nervous and vascular structures, in particular, branches of the superficial temporal artery.

The conflicts that may occur between the nerves and the myofascial and vascular structures could be involved in the etiopathology of temporal headache. The nerves involved are the zygomaticotemporal branch and, less frequently, the auriculotemporal branch of the trigeminal nerve. Owing to this, neurectomy and decompression of the nerves are both considered appropriate treatment for temple migraine.

Moreover, the lower temporal compartment contains the temporal branches of the facial nerve, running through the roof of the compartment parallel to the line of attachment of the inferior septum within a thin fat pad. They are predominantly located cephalad to the sometime duplicated sentinel vein, but thin inconstant nerve branches can run also caudal to it. The gross path corresponds to a line going from 0,5 cm below the tragus to a point approximately 1,5 cm above the later part of the ipsilateral eyebrow. The individual variability is very consistent and therefore the surgical approach should be judicious, in order to spare both nervous and vascular structures [5,6].

The zygomaticotemporal branch of the maxillary division originates from the bifurcation of the zygomatic branch of the trigeminal nerve after crossing a canal in the zygomatic bone it reaches the anterior part of the temporal fossa; 17 mm posterolateral and 6,5 mm cephalad from the palpebral fissure it perforates the deep temporal fascia and arborizes within the subcutaneous tissues to innervate the skin of the temporal area. There are also accessory nerves, which can be located superiorly, immediately adjacent or posterolateral to the main branch. The last one runs horizontally and connects with the auriculotemporal branch of the mandibular division.

A recent study found three potential courses for the path of the nerve from the orbit to the subcutaneous tissues. In almost 50% of the specimens there was no intramuscular course to be found: the nerve bores the fascia within the temporal fossa. This may relate to the percentage of non-responders to the surgical decompression. In the other cases an intramuscular path to the temporal muscle was found for the nerve, either very short (22%) or long and tortuous (28%). In about one third of the population there are two branches, which in some cases (6%) pass through two different foramina [5].

Furthermore, the auriculotemporal nerve represents a minor trigger site for temple headache. It is a branch of the mandibular division of the trigeminal nerve which runs behind



the temporomandibular joint adherent to the parotid gland. It then turns superiorly behind the joint and ascends over the posterior portion of the zygomatic arch. Here, it can leave up to four branches running cranially within the layers of the temporoparietal fascia.

A significant relationship with the superficial temporal artery was found in 34% of the cases: the nerve runs close to it in the soft tissues of the temple region, representing the potential vascular compression point. The artery can bifurcate below or above the superior margin of the zygomatic arch with three possible patterns. In 60% of the cases the artery crosses the auriculotemporal nerve in one site, located approximately 107.88 mm lateral to the midline and 37.53 mm cranial to the nasion-lateral orbit line. In the other cases either the nerve crosses the artery or they coil together for a mean length of 21 mm. This spiral interaction begins about 123 mm lateral to the midline and 25 mm cranial to the nasion-lateral orbit line and ends 117 mm lateral to the midline and 38 mm cranial to the nasion-lateral orbit line.

There are also two other trigger points associated to myofascial structures, particularly to the pre auricular fascial bands in the sub-superficial fascial layer. The first one is located average of 13.1 mm anterior and 5.0 mm superior to the most antero superior point of the external auditory meatus, while the second is centered at an average of 11.9 mm anterior and 17.2 mm superior to the same landmark [5,11].

### **2.3. Occipital region**

The occipital region is an unpaired and median anatomic region corresponding to the posterior part of the cranium. It is composed by five layers: first the skin, very thick and adherent to the underlying planes, followed by a richly vascularized subcutaneous tissue and the muscular-aponeurotic layer, composed by the posterior muscular bellies of the occipitalis muscle and the epicranial aponeurosis (galea aponeurotica). Then there is a loose areolar tissue, poor of connective tissue attachments; its laxity allows the scalp to slide on the skull and justifies the ease of surgical dissection in this area. Moreover, it is possible to create flaps without risk of damaging vessels and nerves, since these structures run in the superficial fascia [3,5,6].

The common occipital headache symptoms here can be caused by the compression of the greater, lesser and third occipital nerves. This is due to the presence of muscular and fascial entrapments and also because of their interaction with the vascular structures [3,5,6,12-15].

The greater occipital nerve originates from the medial branch of the C2 dorsal root. It curves to reach the occipital region, running caudal to the inferior oblique muscle and sometimes piercing it. Then it reaches the semispinalis muscle, where it is possible to identify the deepest potential compression point of the nerve. The average location is 20.13 mm from the midline and 77.38 mm inferior from the occipital protuberance [6]. The course of the nerve in the area

of the superior nuchal line is variously described, because of the large anatomical variability that these structures present. According to some authors, the nerve arches medially to the semispinalis muscle, boring the fascial plane, while others describe it piercing the muscles themselves: the semispinalis in the vast majority of cases (90% of cases), the inferior oblique or the trapezius [3,5-11]. The latest studies have shown the exact location of the intramuscular course of the nerve: it is located 3 cm below and 1.5 cm lateral to the occipital protuberance [3,5]. The point of muscle penetration has a mean horizontal distance from the midline of 11 mm on the left and of 11.8 mm on the right. The mean vertical distance from the line passing at the level of the lowest portion of the external auditory canals is 26 mm on the left and 27mm on the right. The second trigger point can be found at its entrance into the deep fascia underlying the semispinalis or the muscle itself [3,5,6]. The third and the fourth points are located respectively by the entrance of the nerve in the semispinalis capitis and trapezius muscles. The fifth point of possible compression is the where the nerve pierces the tendinous insertion of the trapezius into the nuchal line. In fact in the surgical decompression of the nerve the semispinalis capitis and the trapezius, together with the splenius and the occipital muscles are resected with multiple myotomies. The sixth possible compression point is related to the close relationship found between the great occipital nerve and the occipital artery in the region of the superior nuchal line. This artery is the main vessel running through the occipital area. It arises from the external carotid artery and it runs medially to the mastoid process on the temporal bone. It then reaches the occipital region, boring the deep cervical fascia between the sternocleidomastoid and the cranial attachment of the trapezius. At this point it can be found in the subcutaneous layer leaving many convoluted branches and anastomosing with the contralateral artery [3]. In more than 50 % of the cases an intimate anatomical relationship was found. There are two possible types of interaction: they can coil together (70%) with a mean length of interaction being 37.6 mm and its caudal most aspect a 25.34 mm from the midline and 24.91 mm caudal to the horizontal line through the occipital protuberance; the mean location of the cranial most aspect of the artery-nerve relationship in this group was 42.09 mm from the midline and 0.97 mm caudal to the horizontal line through the occipital protuberance. The other possibility is a simple crossing (30%) with the nerve passing superficial to the artery 30.27 mm lateral to the midline and 10.67 mm caudal to the horizontal line through the occipital protuberance [3,5,6].

Furthermore, minor trigger sites are also described in this area [3,5,6]. They are related to the lesser and to the third occipital nerves, which can be similarly compressed by fascial bands and the occipital artery branches. If the lesser occipital nerve is affected it can be responsible of laterally located pain symptoms. It arises from C2 or rarely from C3 dorsal root, it emerges from the posterior border of the sternocleidomastoids, seldom piercing it, and then ascends along it. The emergence point was found with a 3 cm diameter located 6.5 cm from midline and 5.3 cm below the line drawn between the two external auditory canals. When symptoms

concern the midportion of the occipital region the third occipital nerve is involved. It is the medial branch of the posterior division of the third cervical nerve and it travels deeply along the semispinalis. It then exits the overlying trapezius muscle or the fasci, emerging in an area 4 cm in diameter centered 1.3 cm from midline and 6.2 cm below the line between the two external auditory canals [3,5,6,11].

### **3. Surgical Treatment of Migraine**

#### **3.1. Frontal trigger site**

Initially, patients who suffered from frontal migraine headache due to muscle compression underwent a procedure developed by Guyuron et al., in which hyperexcitability and inflammation of supraorbital and supratrochlear nerves were eliminated through selective myotomies of depressor supercilii, corrugator supercilii, and procerus muscles, using a transpalpebral approach. The frontal trigger site was approached by means of incision the supratarsal crease involving up to two-thirds of the medial limit of the caudal portion of the conventional upper blepharoplasty incision. After a skin–orbicularis oculi muscle flap was raised above the level of the septum and the orbicularis muscle in a cephalic direction. The depressor supercilii muscle was exposed and resected as completely as possible, protecting the supraorbital nerve and supratrochlear nerve to allowed exposure of the corrugator supercilii muscle. After excision with electrocautery of the corrugator supercilii, lateral fibers of the procerus muscle encasing the supratrochlear nerve were also removed. Fat was then harvested either from the medial fat pad of the upper lid or from an area deep to the deep temporal fascia above the zygomatic arch, if endoscopic ablation of the zygomaticotemporal branch of the trigeminal nerve was performed concomitantly, and placed to fill the depression left following resection of the corrugator supercilii muscle and to cushion the nerves [6-8]. The supraorbital nerve, a sensory branch of the ophthalmic division of the trigeminal nerve, exits the orbit by passing over the supraorbital ridge or via a notch or foramen before diving into a superficial and deep branch and is intimately related to the corrugator supercilii in 78% of patients. While incomplete resection of the glabellar muscle group may account for persistent migraine in some patients, the supraorbital foramen (present in 25% of patients) may represent an additional compression site. Since 2002 Guyuron has performed a supraorbital foraminotomy during release of the supraorbital nerve if encountered during resection of the corrugator. As regards the effectiveness of transpalpebral nerve decompression in contrast with the endoscopic approach, a transpalpebral approach did not allow myotomies to be complete, failing to remove more than one third of the corrugator supercilii muscle transverse portion. The whole corrugator supercilii muscle might be removed by means of an endoscopic approach, which was thus claimed to be more thorough and appropriate for this purpose. Endoscopic nerve decompression, however, was not performed on patients with long foreheads (8 cm measured from the anterior hairline to the supraorbital ridge) or on patients with significant curvature to the forehead, as endoscopic

access would have been difficult to impossible. It relies on 3–6 access incisions 1.5–2 cm in length, located 1–2 cm behind the anterior hairline. Two distinct surgical instruments, an endoscope and a dissector, are generally used. In an effort to reduce the invasiveness of the current endoscopic techniques, we described our minimally invasive, endoscopic selective myotomy technique with a single access, performed with a specifically modified endoscope (Karl Storz, Tuttlingen, Germany) and without the need for general anesthesia [12-15]. With the patient supine and the head in a neutral position, frontal trigger nerves are located. Skin markings are drawn above the eyebrow bilaterally, at the mid-pupillary line (supraorbital nerve) and 1 cm medially (supratrochlear nerve). In this minimally invasive technique for forehead headache treatment, local anesthesia with diluted 40cc Carbocaine 1% + 40cc NaCl 0.9% and 20cc sodium bicarbonate 8.4% is injected in the forehead, between the glabellar region and about 2cm behind the anterior hairline. The infiltration of local anesthetic allows not only anesthesia but also the undermining of the tissues and the creation of a space between the periosteum and adjacent tissues to facilitate endoscopic visualization. A single 1.5-cm incision is then performed on the mid-line, 1 cm behind the frontal hairline. The dissection of all tissues (cutaneous, subcutaneous, aponeurotic galea) until periosteum is reached in the subgaleal plane. This location is chosen so that the postoperative scar will be hidden in the patient's hair. Tissues all over the forehead bilaterally are undermined in the subgaleal plane through the hairline incision by means of long scissors. Undermining must be done carefully, particularly when the inferior limit of the undermining area (superciliary region) is reached, in order not to damage supratrochlear and supraorbital nerves. The lateral anatomic limit of the undermining area is the temporal region, bilaterally. In order to lifting the frontal skin during the endoscopic procedure and better visualizing the anatomic structures, Nylon 1–0 sutures are placed in the superciliary region at each side of both supratrochlear and supraorbital nerves bilaterally. Then a suction of blood and residual anesthetic fluid the entire undermined forehead is performed through the hairline incision before inserting the endoscope and whenever the endoscopic view is not clear. Our modified endoscope (Karl Storz, Tuttlingen, Germany) consists of a 9-mm trocar with an air/insufflator/ suction triple valve, a straight Hopkins telescope with fiber-light transmission, a Wittmöser operating sheath with a connection for high-frequency diathermy, and a specifically designed, elliptical-tipped wire loop electrode for electrocautery. The modified endoscope is inserted through the incision in the subgaleal plane and used to perform endoscopically assisted section of the corrugator supercilii, depressor supercilii, and procerus muscles bilaterally, with the purpose of decompressing the supraorbital nerve and supratrochlear nerves bilaterally. During this procedure, it is important to dissect every part of the muscle, which receives facial nerve fibers responsible for contraction of the muscle itself, in order to prevent irritation to surrounding nerves from the muscle's movement. At the end of the procedure, after an accurate hemostasis the cutaneous access is closed with absorbable suture, without any drainage, and a compressive bandage is positioned all around the patient's head.

### 3.2. Temporal trigger site

The zygomaticotemporal branch of the trigeminal nerve travels between temporalis muscle and the lateral orbital wall and is commonly transected during craniofacial or aesthetic forehead surgery, with no reported consequence. Transcutaneous tattooing of the nerve site by the measurement from the lateral canthus (17 mm lateral and 6.5 mm cephalad to the lateral canthus) could be used to forewarn the surgeon about the location of the nerve. Under local anesthesia two incisions measuring 1.5 cm are made on each side located approximately 7 cm and 10 cm from the midline. Dissection under the incisions is realized by scissors to expose the deep temporal fascia and with a periosteal elevator is conducted medially, laterally, cephalad, and caudally to accommodate the endoscope. To reach this nerve safely, it is crucial to identify the deep temporal fascia beneath the scalp incision and to continue the dissection in this plane. The zygomaticotemporal branch of the trigeminal nerve is then exposed, isolated and avulsed on one side, removing approximately 2.5 cm of the nerve, while on the other side; it is decompressed by widening the fascia opening and removing the zygomaticotemporal artery. The proximal nerve end is allowed to retract into temporalis muscle to reduce the risk of neuroma formation. Some surgeons prefer locate the zygomaticotemporal branch of the trigeminal nerve through a transpalpebral incision [5,6]. A careful dissection along the inferior lateral orbital rim over the deep temporal fascia is performed. The superficial temporal fascia is carefully lifted off the deep temporal fascia with an elevator and a lighted retractor to retract tissue and protect the sentinel vein and the temporal branch of the facial nerve. Careful dissection around the vein to identify the zygomaticotemporal nerve is performed, and once identified, the zygomaticotemporal nerve is avulsed. Both avulsion neurectomy and decompression of the zygomaticotemporal branch of the trigeminal nerve are equally effective methods for the treatment of temporal migraine headache but decompression as the first option. The avulsion remains a logical alternative when decompression is technically difficult or when the zygomaticotemporal branch of the trigeminal nerve has multiple branches without concomitant vessels or tight fascia bands. Our experience about surgical treatment of temporal migraine concerns on open decompression of the zygomaticotemporal branch of trigeminal nerve. In first moment, the patient indicates the trigger point in temporal region, after we inject local anesthetic and we make a 3 cm cutaneous incision in the same area. By the blunt tip scissors, we perform the dissection up to the deep temporal fascia. We open the inferior temporal septum keeping above the fascia to expose the inferior temporal compartment that contains the zygomaticotemporal nerve, sentinel vessels and temporal branches of facial nerve. After operating this septum, it is imperative that the level of dissection hug the floor of the space, that is, directly on the deep temporal fascia, because the temporal branches of facial nerve course through the roof of the lower temporal compartment immediately abutting the inferior temporal septum. Then we perform the zygomaticotemporal nerve decompression realizing it from constricting temporal muscle fibers, without any avulsion. When the patient

describes a pulsing pain in temporal region, we perform the electrocautery of sentinel vessels. Eventually, the cutaneous access is closed with absorbable suture and a compressive bandage is positioned all around the patient's head.

### 3.3. Occipital trigger site

The purpose of the surgical treatment of Site IV is to remove the potential compression points of the greater occipital nerve along its course throughout the semispinalis and the trapezius muscles to the subcutaneous tissue of occipital scalp. The avulsion of the third occipital nerve (TON) during the occipital migraine surgery does not improve clinical outcomes. When this nerve is encountered during the dissection of GON it is sacrificed but the superficial compression of the TON does not contribute significantly to the onset of occipital migraine headaches. Guyuron et al. in 2005 described their surgical procedure to treat occipital migraine [6]. With the patient prone, under general anesthesia, a horizontal 5- to 6-cm incision is made approximately 3 cm below the occipital protuberance. After reaching the trapezius muscle in the deep anatomical planes, a vertical incision is made over his fascia, where are present 1 to 3mm of vertically oriented muscle fibers. If the avulsion of TON is performed, the third occipital nerve is allowed to retract into the portion of the semispinalis capitis muscle to avoid the scar entrapped it, causing a painful neuroma. If the trapezius muscle extends to the midline raphe, it is divided and retracted laterally and the semispinalis muscle is then further exposed. The trunk of the GON is located usually approximately 1.5 cm from the midline and 3 cm caudal to the occipital protuberance and is identified when the dissection continues under the trapezius fascia and muscle laterally. The GON is released from surrounding muscle and any fascial bands overlying the nerve until the subcutaneous plane is reached. Furthermore, a 2 cm long segment of the semispinalis capitis muscle between the nerve and the midline raphe is removed. When the occipital artery is ectasic and entangled with the nerve the ligation is performed and the GON is separate from the remaining muscle by placing a laterally elevated subcutaneous flap deeply to the nerve. This procedure is then repeated on the opposite side if indicated. Sometimes the muscle fibers of semispinalis capitis splitting the nerve within, in this case they are also released. When the nerve is within the trapezial tunnel, the dissection is carried distally releasing the GON. This tunnel is the site where the greater occipital nerve penetrates through the trapezial fascial attachments to the occiput and it has 1 to 2 cm oblique superolateral direction where often contains angiolymphatics, another possible compression variable that is removed. Our surgical GON bilaterally decompression technique is performed under local anesthesia with the patient prone. After injecting of diluted 40cc Carbocaine 1% + 40cc NaCl 0.9% and 20cc sodium bicarbonate 8.4% , a horizontal occipital scalp incision 6 cm in length is made along the superior nuchal midline to expose subcutaneous structures. No trichotomy is needed, and the scar from the incision will be hidden in the patient's hair. First of all the dissection of occipital muscle is performed, then a minutely separation of the trapezius

fibers expose the GON and the semispinalis capitis muscle. Trapezius and semispinalis capitis muscle are carefully undermined following the nerve course as far as possible.

Subsequently the splenius capitis muscle, which is located laterally behind of GON, and the occipital vascular bundle are isolated from the nerve. The proximity of the occipital artery to the greater occipital nerve often seems to cause nerve compression and paroxysmal, throbbing pain. In fact, sometimes the nerve irritation might be due by the pulsing activity of the occipital artery may be more distended than expected. In this case the ligation of occipital artery is performed. At the end of the procedure, after an accurate hemostasis the cutaneous access is closed with absorbable suture, without any drainage. Pre surgical planning should always include questioning for potential pain at lesser occipital nerve compression points. Furthermore, residual migraine pain after occipital nerve decompression of the greater occipital nerve may be attributable to lesser occipital nerve (LON) entrapment and should be evaluated in non responders and partial responders. The occipital artery and fascial bands along its course could potentially compress the lesser occipital nerve. If patients, in addition to compression of GON, refer pain and symptoms specific to the lesser occipital nerve, a separate incision is made over this nerve at the posterior border of the sternocleidomastoid muscle and it was avulsed. When is present an unilateral lesser occipital nerve compression, over the path of the LON localized along the middle third of the posterior margin of sternocleidomastoid, laterally to the first incision of GON a 3 cm excision is performed. The lesser occipital nerve can be decompressed or excised and its proximal stump implanted into muscle. When both bilateral greater occipital nerve and lesser occipital nerve decompression is performed two separate incisions are made, one on each side, each to access the ipsilateral greater occipital nerve and the lesser occipital nerve. As regards our experience, when trigger site is identified in the LON a 4-cm-long lateral occipital incision is performed, followed by the dissection of occipital, trapezius and a portion of sternocleidomastoid muscles, thus freeing the nerve. While if patients present both trigger points an 8-cm-long medial incision is made and dissection of all above mentioned muscles and vessels (occipital arteries) and isolation of both nerves are performed [15].

### **3.4. Auriculo-temporal nerve**

Auriculotemporal neuralgia has been described in the neurology literature as a syndrome “characterized by attacks of paroxysmal, moderate to severe pain on the pre auricular area, often spreading to the ipsilateral temple”. Chimet al. in a study concerning the anatomical variations of compression points of the auriculotemporal nerve, they have identified three specific points that could be surgically treated [5]. The pre auricular fascial bands compression points (compression points 1 and 2) in the preauricular course of the auriculotemporal nerve were found centered at 13.1 and 11.9 mm anterior and 5.0 and 17.2 mm superior to the most anterosuperior point of the external auditory meatus. The other compression point (Compression

point 3) is represented by the crossover in the temporal scalp between the auriculotemporal and the superficial temporal artery. Guyuron et al. developed the technique for endoscopic decompression of the zygomaticotemporal branch of the trigeminal nerve, and recently, it has been recognized that the failure of site II surgery may be because of the lack of identification and decompression of the auriculotemporal nerve. For this reason commonly the auriculotemporal nerve decompression is performed in conjunction with the zygomaticotemporal decompression [5,6]. We report the endoscopic surgical techniques to decompression-avulsion of the auriculotemporal nerve [5,6,15]. The point of maximal tenderness is marked and Doppler findings to determinate vessel location may be used to avoid injury to the surrounding nerves or difficulty to place the endoscopic access devices. Both techniques can be combined with decompression of the trigger site 2, in that case auriculotemporal nerve is addressed first. In local anesthesia, 5–7 port incision is designed for site II surgery and the 1.5-cm lateral incision is made and is extended anteriorly if necessary. Dissection to identify the vessel and nerve should be performed with blunt tip scissors along the direction of the vessel. The vessel and nerve are commonly found in the superficial layers and along the superficial temporal fascia. Use of blunt-tip bipolar and regular suction is enough to safely ligate the vessel and nerve after identification. Although the area of dissection is far cephalad to the temporal branch of the facial nerve, caution should be exercised. The deep temporal fascia is then identified and placement of endoscope is performed. If one is concerned about an unusually anterior temporal artery causing compression and pain (scars beyond the hairline or proximity to the temporal branch of the facial nerve), ligation of the main trunk of the auriculotemporal nerve in the pre auricular area is chosen. The area of maximal tenderness above the temporomandibular joint, which hosts the main trunk of the auriculotemporal nerve, is accessed, and the vessel and nerve are ligated in this area. A 1.5-cm incision is performed 0.5 cm in front of the tragus and above the temporomandibular joint area with the aid of Doppler. The main trunk of the auriculotemporal nerve is identified first, and the vessel is then located in the deeper plane, commonly associated with another small nerve branch. Caution should be used to avoid injury to the facial nerve, which is deep to the dissection, and to the commonly visualized vein, which is in a more superficial plane. Even with vessel ligation in this area, auriculotemporal nerve decompression and superficial temporal artery ligation in the most lateral port should be done, if possible, because of collateral flow that may still exist. If both areas are to be decompressed, lateral port access and decompression are performed first to ensure better visualization of the artery.

#### **4. Clinical Course**

As stated previously, 30% of MH patients still suffer from debilitating chronic MH since they are refractory to current medical management. Moreover, not all patients may benefit from the existing therapies due to the possible adverse events and contraindications. It's our



shared opinion that patients diagnosed with MH who, despite or not conservative treatment, are still symptomatic may be eligible for the surgery [9]. Being affected by mental illness and children under 16 years are the only excluding criteria.

All procedures are minimally invasive and are performed under local assisted anesthesia as 1-day surgery with an average surgery time of less than 1 hour. No drainage needs to be positioned. Patients should keep ice on the surgical area for 24 h following surgical procedure in order to lower the risk for complication of the postoperative course (e.g. hematoma, bleeding, edema). Patients must be fasting from midnight and may start feeding again since the 2nd hour after surgery. Patients are permitted to resume ordinary activities in 1 week and heavy exercise in 3 weeks. Patients have to medicate each two-day the surgical wound with beta dine and can take a shower since the day after surgery. Stitches have to be removed the 14th post-operative day. The postoperative edema of the upper lid following frontal migraine surgery it's almost a certainty and resolve in the following 3/5 days while the ecchymosis will vanish by the 2nd postoperative week. Boric water applications three times a day may help the process of reabsorption of the edema. As the edema may move in the posterior orbicular space determining the compression of the optic nerve, patients' sight must be assessed during the 12 hours that follow the frontal migraine surgery in order to perform a prompt surgical decompression as soon as the patient reports changes in his/her sight. However it is just an eventual complication that currently we have never observed in our clinical practice.

Patients should fill a daily headache diary and complete MH questionnaires assessing MH parameters following surgery. The same questionnaires are given preoperatively in order to assess changes in the MH. Patients may be seen after initial recovery, at 1 month, and then every 3-month for 1 year.

Almost 90% of the patients can recognize more than one MH trigger site; the surgical deactivation may be performed at all sites during the same surgical procedure [10]. However, we routinely deactivate the main trigger site first, and then a second or third surgery is performed at the remaining sites 3 months after each surgery.

MH recurrence may occur from 1 up to 3 months after surgery; thus the result may be regarded as permanent only after the 3rd postoperative months [5,6,9]. The frontal area has the highest rate of MH relapse [5,6,9].

Furthermore, patients should be informed when signing the informed consent that deactivation of a MH trigger site may unmask secondary headaches in almost 17.8% of patients and that more than one surgery may be needed [9].

## 5. Results

In 2000, Guyuron was the first to show in a retrospective study the relation between MH and corrugator supercilii muscle resection when he reported that 80% patients described elimination or improvement in their headaches following corrugator supercilii muscle avulsion for forehead rejuvenation surgery [4]. This evidence was followed by a prospective study where he reported a 95% rate of either complete alleviation or improvement in MH after a mean follow-up of 1 year [5]. Over the last 15 years, Guyuron conducted several anatomical and clinical studies reporting a reduction of the frequency, duration, and intensity of MH by at least half in 80 to 90% of patients [4-10]. In 2011, Guyuron et al. published a study examining the long-term benefits of migraine surgery where it was reported an 88% success rate after a five-year follow-up (29% completely healed, 59% gained improvement, 12% did not show any change) [8]. Other independent groups reported similar findings using Guyuron's protocols, demonstrating the effectiveness of the procedure and the reproducibility of the results [5,12-15].

From June 2011 till February 2016 we have performed MH decompression surgery over 89 patients with either frontal, occipital or temporal migraine trigger sites. After a mean follow-up of 17 months (range: 3 - 56 months), 93.9% patients reported positive response to surgery, 52.4% had complete elimination of their migraine, while 41.5% referred at least a 50% reduction in MH symptoms, 6.1% patients didn't notice any improvement after the surgery. Patients with frontal migraine trigger site reported a 94% positive response to surgery (32% complete relief and 62% significant improvement), 6% had no change in their symptoms; while patients with occipital migraine had positive response in 93,7% (85,5% complete relief and 8,2% significant improvement), and 6,3% did not get any better. Patients complaining for temporal MH had 83.3% positive surgical outcome (50% complete MH elimination, 33.3 significant improvement), and 16.7% patients did not noticed any improvement.

Overall response rates are almost the same as no significant differences can be found between the trigger sites. However, occipital migraine surgery leads to higher rates of complete relief of symptoms than the frontal and temporal and intranasal ones (85,5% vs. 32%, 50%, and 34% respectively). This may be attributable to a more complete and thorough decompression since the IV and VI sites surgeries are technically easier to perform.

All patients continue to experience a quality of life better than before surgery and all would have the surgery again.

As reported in literature, we do have patients that reported complete relief during the first 30 to 60 days postoperatively and then gradual (though improved) return of symptoms to the treated region [5,6,9]. This event was most common with frontal migraine. The recurrent

headaches were often described as less intense, more “treatable” and improvement were beyond baseline. These events were very disappointing for both the surgeon and the patients; no exact mechanism has been found but it seemed to coincide directly with returning nerve function.

Average frequency, intensity, duration, and Migraine Headache significantly improve. The mean number of days lost from work usually reduces by four times.

Since surgical deactivation of peripheral sensory nerves has demonstrated to be effective for the treatment of MH, positive surgical outcome also have significant economic value as it lead to cost savings by cutting expenses associated with medications, doctor visits, and other financial burdens relating to migraine headache [2]. The median total cost for MH treatment drops from \$5820/year preoperatively to \$900/year postoperatively with a total median cost reduction of \$3949.70/year postoperatively [2]. Surgery has a mean cost of \$8378, thus MH surgery is cost-effective, reducing both direct and indirect cost; it has also essential social effects by improving the working performances and increasing the participation in daily living activities.

Our results are similar to those reported in literature by other authors [3,6,8,9]. Global positive response rates did not show any significant differences, ranging between 80 and 95%; frontal MH is the most frequent one but it’s also the one that more often either recurred or unmasked a 2nd trigger sites after decompression surgery [8,9]. Occipital MH instead has the better surgical outcome with the highest resolution rate [6,8].

We believe that this difference may be caused by the compression of the dilated occipital vessels, which is often observed during the surgery and, once removed, lower the risk for recurrence. Compression over frontal and temporal trigger site is usually consequent to muscular impingement; thus scar tissue might connect again the divided muscular fibers recreating some kind of nerve compression.

Elimination rate of frontal migraine has the highest variability, performed either by endoscopic or trans-palpebral approach. Poggi reported a 16.7% complete elimination rate of frontal MH, Guyuron described a 57.1 resolution rate while Janis gained complete relief of frontal MH only in 8.7% patients [5]. This discrepancy may partially be explained by variation in the technique: Guyuron and Poggi performed the frontal glabellar muscle avulsion, while Janis resected the only corrugators [5,6]. Bearden and co-workers reported 58% complete relief of frontal MH following trans-palpebral corrugator muscle resection [5]. We have reported a 32% resolution of frontal MH by means of endoscopic resection of glabellar muscles. Thus, complete avulsion of procerus, corrugator and depressor supercillii muscles may lead to higher elimination rate, but no clear evidences have been reported.

Complete resection of the glabellar muscles can be easily obtained thanks to the

magnification offered by the endoscopic technique, which provides a better means to preserve the nerves, resect the muscles and identify secondary nerve branches [12-15]. Nevertheless, patients that undergo trans-palpebral access surgery may experience higher rate of complication (e.g. risk for intra-operative bleeding, more noticeable scars) and a more invasive procedure than if it would have been performed endoscopically; firhter more, patients show lower compliance to receive an open surgery. Therefore, we agree with the common belief that the endoscopic approach for frontal migraine therapy should be considered as first choicesince it has been demonstrated that odds ratio for improvement or elimination are higher if compared with the trans-palpebral access [4-6,12-15]. Trans-palpebral nerve decompression should be performed when a forehead length of 8 cm or more contraindicates the endoscopic approach.

Chepla and co-worker showed that patients presenting supraorbital foramen instead of the supraorbital notch experienced higher success rate after resection of glabellar muscle group with foraminotomy, thus supporting the hypothesis that the supraorbital nerve may be constricted within the foramen leading to frontal migraine headaches [5].

Furthermore, it emerged that some factors may affect the surgical outcome. Migraine surgery failure seem to be associated to increased intraoperative bleeding, surgery on fewer trigger sites, and history of significant head and neck trauma; while older age of migraine onset, higher rate of visual symptoms, surgery at site I or II, and deactivating all four operative sites are associated with migraine surgery success [5,8,9]. The exact relationship between history of head and neck trauma, age of onset, visual symptoms and response to surgery is not understood. Patients complaining multiple trigger sites will undergo multiple decompression surgeries addressing even minor triggers, this is likely the explanation for better outcome associated with greater number of operative locations. Intra operative bleeding may interfere with optimal surgical outcome by promoting scar tissue formation. Intra operative bleeding and blood pressure must be controlled aggressively in order maximize success rate. MH characteristics (e.g. frequency, duration, and amount of drugs needed) also seem to affect the surgical outcome, milder MH have higher chances of improvement in comparison to more severe ones, which are more likely to recur postoperatively [5,8,9]. Preliminary Botox infiltration does not affect the surgical success [10].

## 6. Complications

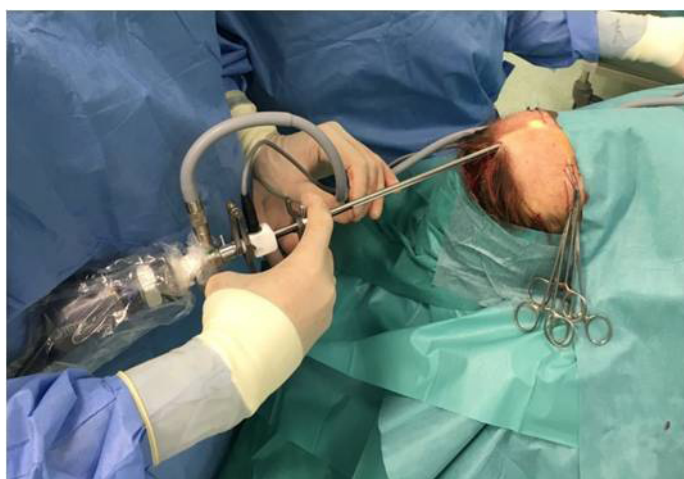Migraine surgery is regarded as a minimally invasive procedure, thus no concerning side effects are usually reported.

All patients undergoing frontal decompression surgery with endoscopic approach will experience frontal and upper eyelid edema of various degrees. Usually the edema resolves by the 5th postoperative days. Ecchymosis of both upper, lower eyelids and zygotic regions also follow surgery and usually vanish by the 2nd postoperative week. No treatment needs

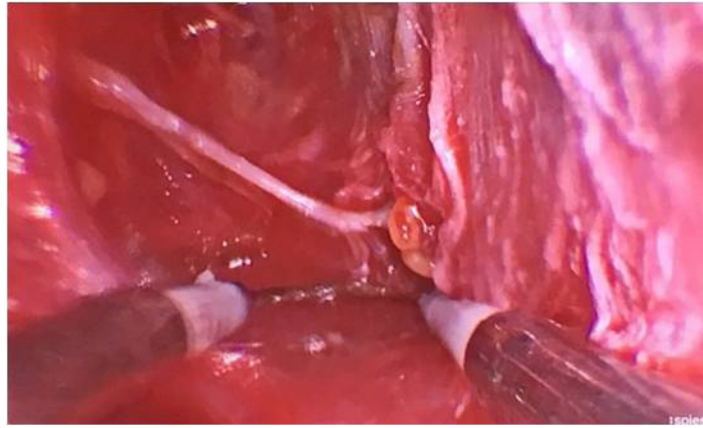
to be given as these collateral events resolve by themselves; boric water applications three times a day may help the process of re absorption of the edema. As previously stated, the only hypothetical serious complication, that may occur within the 12 hours following the surgery is the compression of the optical nerve due to the drop of the edema into the posterior orbicular space whenever the subgaleal dissection is carried out beyond the orbital rim. Prompt recognition of patient's sight modification is mandatory in order to urgently decompress the optic nerve. Decreased glabellar muscles activity till complete elimination may occur depending on the technique applied. Slight asymmetric eyebrow movement may be also noted [6]. Patients with particularly thin skin of the frontal region may develop postoperative burn-like scar (2%) as a consequence of the endoscopic electrocautery.

Any nerve avulsion may be associated with the formation of neuromas [5]. Nevertheless, avulsion of neither the zygomaticotemporal nor the auriculotemporal branches of the trigeminal nerve is reported to lead to the formation of neuromas [5,8].

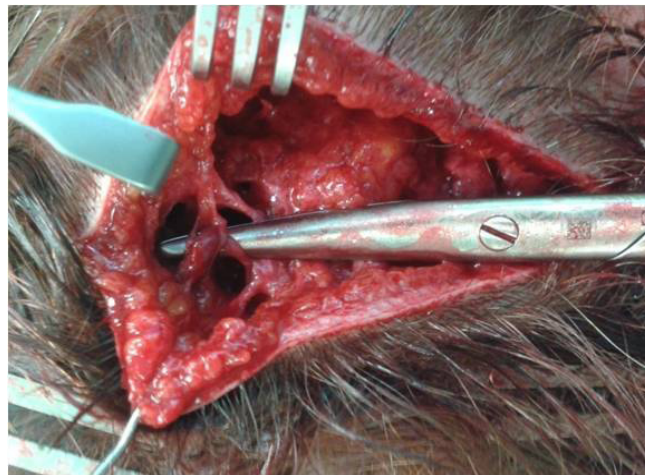Temporarily anesthesia occurs in all patients, which last 163 days on average [5,8,12-15]. Other minor and transient complications reported are: lasting occipital numbness at 1 year (5.7%), intense itching after surgery (5.7%), hypertrophic scar (2.7%), incisional cellulitis (1%) that resolve with oral antibiotics, transient mild incisional alopecia or hair thinning (5%), lasting neck stiffness at 1 year (9%), postoperative epistaxis (4.8%), early sinusitis in the recovery period following septum and turbinate surgery (4.8), slight septal deviation recurrence (12.9%) [3,5,8,9,12-17]. Almost 54% patients undergoing temporal surgery reported slight hollowing of the temple [5]. All patients that were refractory to surgery did not report worsening in their MH at any follow-up. Since the operation does not cause any serious complications or side effects, it can be recommended to patients with severe forms of migraine and symptoms of drug dependency. These patients still have a 50 percent chance of responding with partial or even total relief of their headaches.



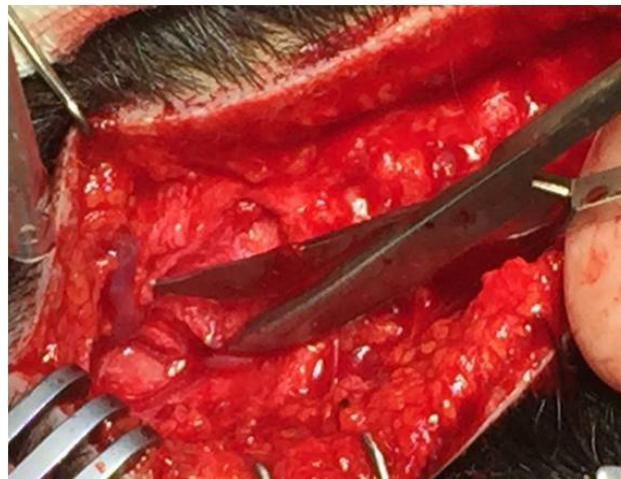**Figure 1:** The endoscope is inserted through one incision in the subgaleal plane until the superciliary region is reached, in order to perform the section of the corrugator supercillii, depressor supercillii, and procerus muscles (this picture belongs to Prof. Edoardo Raposio).



**Figure 2:** Endoscopically assisted section of the corrugator supercilii and depressor supercilii muscles (this picture belongs to Prof. Edoardo Raposio).



**Figure 3:** Dilated left occipital artery constricting the left great occipital nerve (this picture belongs to Prof. Edoardo Raposio).



**Figure 4:** Aberrant left occipital arteries compressing the left occipital nerve (this picture belongs to Prof. Edoardo Raposio).

## 7. References

1. World Health Organization. The Global Burden of Disease, 2004 Update. World Health Organization; 2004; Geneva, Switzerland.
2. Faber C, Garcia RM, Davis J, Guyuron B. A Socioeconomic Analysis of Surgical Treatment of Migraine Headaches. *Plast Reconstr Surg.* 2012; 129: 871-877.
3. Chmielewski L, Liu MT, Guyuron B. The Role of Occipital Artery Resection in the Surgical Treatment of Occipital

Migraine Headaches. *Plast Reconstr Surg.* 2013; 131: 351e-356e.

4. Guyuron B, Varghai A, Michelow BJ, Thomas T, Davis J. Corrugator supercilii muscle resection and migraine headaches. *Plast Reconstr Surg.* 2000; 106: 429-437.

5. Janis JE, Barker JC, Javadi C, Ducic I, Hagan R, Guyuron B. Mint: A Review of Current Evidence in the Surgical Treatment of Migraine Headaches. *Plast Reconstr Surg.* 2014; 134: 131-141.

6. Guyuron B, Kriegler JS, Davis J, Amini SB. Comprehensive Surgical Treatment of Migraine Headaches. *Plast Reconstr Surg.* 2005; 115: 1-9.

7. Guyuron B, Reed D, Kriegler JS, Davis J, Pashmini N, Amini S. A Placebo-Controlled Surgical Trial of the Treatment of Migraine Headaches. *Plast Reconstr Surg.* 2009; 124: 461-468.

8. Guyuron B, Kriegler JS, Davis J, Amini SB. Five-Year Outcome of Surgical Treatment of Migraine Headaches. *Plast Reconstr Surg.* 2011; 127: 603-608.

9. Punjabi A, Brown M, Guyuron B. Mint: Emergence of Secondary Trigger Sites after Primary Migraine Surgery. *Plast Reconstr Surg.* 2016; 137: 712e-716e.

10. Guyuron B, Nahabet E, Khansa I, Reed D, Janis JE. The Current Means for Detection of Migraine Headache Trigger Sites. *Plast Reconstr Surg.* 2015; 136: 860-867.

11. Tolhurst DE, CarstensMH, Greco RJ, Hurwitz DJ. The surgical anatomy of the scalp. *Plast Reconstr Surg.* 1998; 102: 478.

12. Caruana G, Bertozzi N, Boschi E, Grieco MP, Grignaffini E, Raposio E. Endoscopic forehead surgery for migraine therapy: Personal technique. *Ann Ital Chir.* 2014; 85: 583–586.

13. Raposio E, Caruana G. Mint: Frontal endoscopic myotomies for chronic headache. *J Craniofac Surg.* 2015; 26: 201–213.

14. Caruana G, Grignaffini E, Raposio E. Endoscopic forehead muscle resection for nerve decompression: a modified procedure. *Plast Reconstr Surg Glob Open.* 2015; 7: e342.

15. Raposio E, Caruana G. Mint: Minimally Invasive Endoscopic Surgical Treatment of Headache. In: “Atlas of Endoscopic Plastic Surgery” (Raposio E., Ed.), 17-23, Springer, New York, 2016.

16. Raposio E, Caruana G. Tips for the surgical treatment of occipital nerve-triggered headaches. *Eur J Plast Surg.* 2017; 40: 177-182.

17. Polotto S, Simonacci F, Grignaffini E, Grieco MP, Raposio E. Surgical treatment of frontal and occipital migraines: A comparison of results. *Plast Reconstr Surg Glob Open.* 2016 Mar 18; 4: e653.

This chapter has previously been published in “Current Perspectives on Less-Known Aspects of Headache”, (H. Turker, Ed.), InTech, 2017. Upon request from all the authors, this work is published again in OpenAccess eBooks for greater impact.